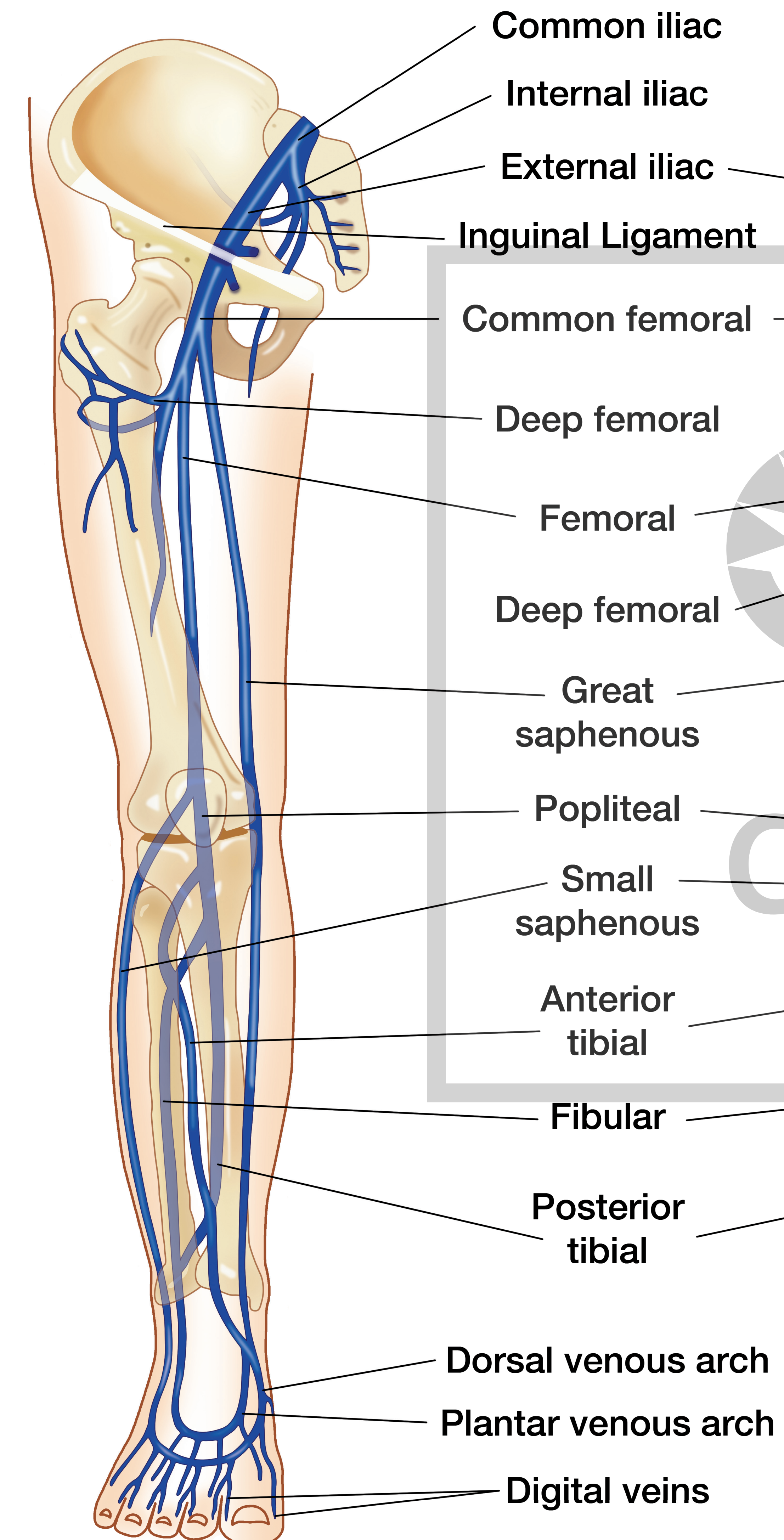


# Venous Anatomy

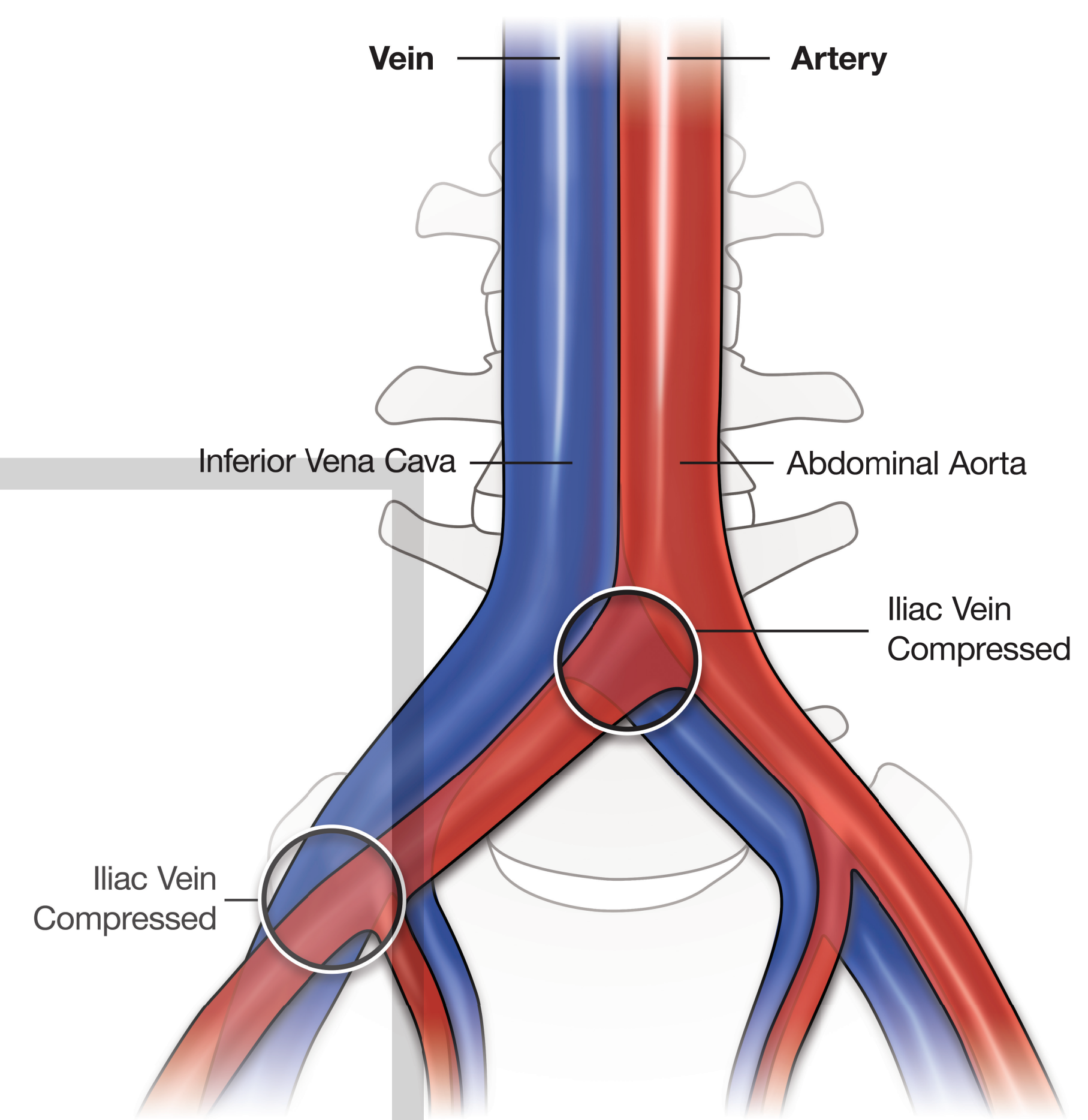
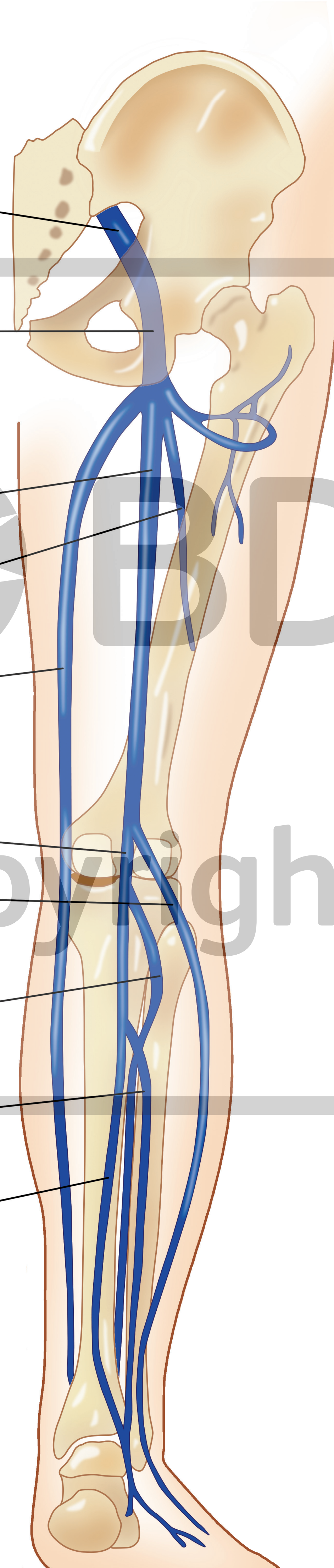
Front View

Back View

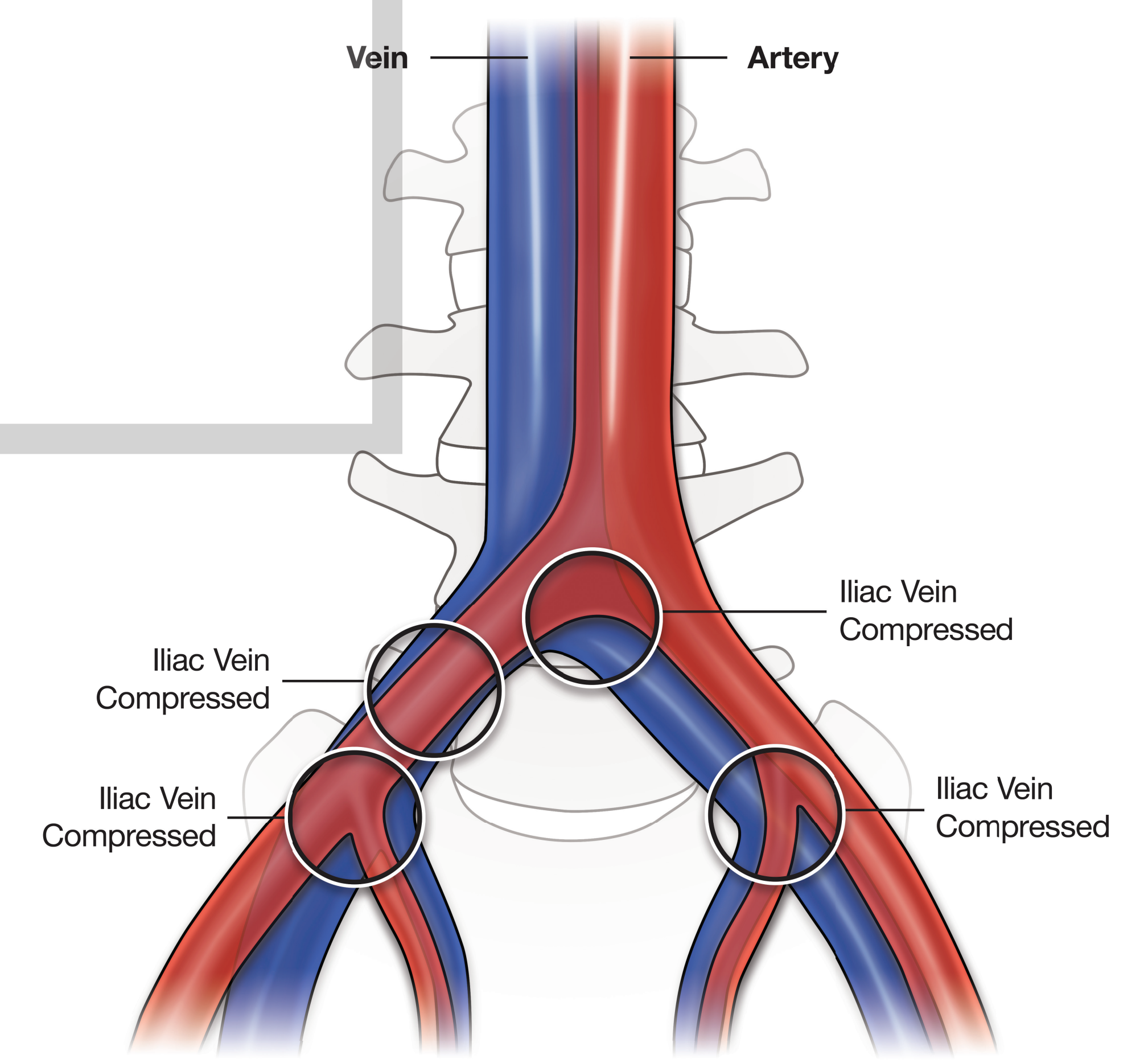
Most Common Compression Points of the Iliac Artery on the Iliac Vein



- Common iliac
- Internal iliac
- External iliac
- Inguinal Ligament
- Common femoral
- Deep femoral
- Femoral
- Deep femoral
- Great saphenous
- Popliteal
- Small saphenous
- Anterior tibial
- Fibular
- Posterior tibial
- Dorsal venous arch
- Plantar venous arch
- Digital veins



Least Common Compression Points of the Iliac Artery on the Iliac Vein



(a)

(b)